·血管介入 Vascular intervention·

覆膜支架植入术治疗肾动脉及肾移植术后假性动脉瘤

管 生, 金 洁, 李明省, 马 南, 刘 朝, 刘继营, 陈 振

【摘要】 **目的** 探讨多种原因所致肾动脉假性动脉瘤的血管内覆膜支架治疗术。**方法** 2008 年 8 月至 2012 年 9 月收治 6 例肾动脉损伤及肾移植术后假性动脉瘤患者, 因不适宜常规介入栓塞而采用血管内覆膜支架治疗。其中外伤 1 例,医源性损伤 1 例,肾移植术后并发假性动脉瘤 4 例。术中支架植入时开始给予抗血小板聚集药,术后给予 3 d 抗凝治疗并同时口服氯吡格雷、阿司匹林半年,之后持续口服阿司匹林。**结果** 6 例中,2 例出血患者术后出血停止且患肾血流灌注保持良好,4 例假性动脉瘤获完全隔绝。随访 2 ~ 34 个月,平均 19 个月。其中 2 例移植肾动脉吻合口假性动脉瘤行髂内动脉覆膜支架植入术后移植肾失功能,1 例术后出现感染,又行移植肾切除术,余均取得满意效果,无症状复发、瘘及狭窄。**结论** 对于不适合常规介入栓塞的肾动脉及肾移植术后假性动脉瘤患者,覆膜支架植入不失为一种可选择的、有效治疗方法,但远期疗效尤其是支架内再狭窄情况有待进一步观察。

【关键词】 假性动脉瘤; 覆膜支架; 肾脏

中图分类号:R543.5 **文献标志码**:A **文章编号**:1008-794X(2013)-07-0545-04

Endovascular covered stenting for the treatment of renal pseudoaneurysm after renal transplantation

GUAN Sheng, JIN Jie, LI Ming-xing, MA Nan, LIU Chao, LIU Ji-ying, CHEN Zhen. Department of Interventional Radiology, the First Affiliated Hospital of Zhengzhou University, Zhengzhou, Henan Province 450052, China

Corresponding author: GUAN Sheng, E-mail: gsradio@126.com

【**Abstract**】 **Objective** To discuss the endovascular covered stenting for the treatment of renal pseudoaneurysms due to a variety of causes. **Methods** During the period from August 2008 to September 2012, six patients with renal pseudoaneurysm caused by renal artery injury or renal transplantation were admitted to the hospital. As the patients were not suitable for conventional embolization therapy, endovascular implantation of covered stent was carried out. The cause of pseudoaneurysm included trauma ($n = 1$), iatrogenic injury ($n = 1$) and renal transplantation ($n = 4$). During stent implantation procedure, anti-platelet aggregation medication was given, and after the procedure anticoagulation therapy was used for 3 days, and oral administration of plavix and aspirin was conducted for half a year, which was followed by continuous oral administration of aspirin. **Results** In 2 patients the bleeding stopped after the endovascular implantation of covered stent and the renal blood perfusion was well maintained, and in the remaining four patients the pseudoaneurysm was completely isolated. During the following-up period lasting 2 – 34 months (mean 19 months), loss of renal function was seen in two patients, who had suffered from pseudoaneurysm at transplanted renal artery anastomotic stoma and had received covered stent implantation of internal iliac artery. One patient developed infection of unknown cause, and removal of transplanted kidney had to be performed. Excellent results were achieved in the remaining patients. No recurrence of symptoms, fistula or artery stenosis occurred. **Conclusion** For renal pseudoaneurysm patients who are not suitable for conventional renal artery embolization therapy, endovascular implantation of covered stent may after all be accepted as an effective and proper treatment although its long-term efficacy needs to be further evaluated.(J Intervent Radiol, 2013, 22: 545-548)

【**Key words**】 pseudoaneurysm; covered stent; kidney

DOI:10.3969/j.issn.1008-794X.2013.07.004

作者单位: 450052 郑州大学第一附属医院放射介入科

通信作者: 管 生 E-mail: gsradio@126.com

肾脏假性动脉瘤是临床少见疾病,文献报道发生率仅 0.09%[1]。各种原因引起的肾内型假性动脉瘤或出血可行常规超选择性载瘤或出血动脉栓塞,肾脏功能不至于严重受损[2]。然而,部分病例因肾动脉主干损伤或移植肾动脉吻合口假性动脉瘤行常规介入栓塞可能导致肾功能不全,需另辟途径。我们成功为 6 例肾脏假性动脉瘤患者进行腔内覆膜支架隔绝术并随访,现报道如下。

1 材料与方法

1.1 一般资料

2008 年 8 月至 2012 年 9 月,6 例肾脏假性动脉瘤患者在我院介入科接受血管内覆膜支架治疗,患者均为男性,年龄 21 ~ 56 岁,平均 40.8 岁。其中外伤 1 例,经皮内镜取石(PCNL)术后 1 例,肾移植术后 4 例。左肾损伤 2 例,右肾损伤 4 例;肾内型 2 例,肾外型 4 例。

1.2 治疗方法

所有患者因术前 CT 或 CTA 检查提示不适于常规栓塞而制定手术方案。手术过程如下:采用 Seldinger 法穿刺股动脉,放置 8 F 血管鞘(美敦力,上海,美国),经血管鞘引入眼镜蛇导管(泰尔茂,北京,日本),行双肾动脉造影,根据患肾假性动脉瘤所起源血管的直径、部位或出血位置选择合适尺寸覆膜支架植入。路径图下经血管鞘和导丝引入支架释放系统,准确定位后释放覆膜支架。即刻血管造影观察是否还有对比剂外溢及载瘤动脉是否通畅。术后患者临床症状消失,生命体征平稳。术中植入支架前 30 min 给予肝素化(肝素钠 100 mg/kg)和抗血小板聚集药(替罗非班 0.4 μg/kg);术后继续抗凝 3 d 并口服氯吡格雷 (波立维)75 mg/d 和阿司匹林 100 mg/d 半年,之后持续口服阿司匹林每天 100 mg。术后 3、6、12 个月行影像检查及肾功能复查。

2 结果

6 例患者均成功植入覆膜支架, 破口封堵良好(图 1)。术中应用 Fluency 覆膜支架 1 例,Jostent 覆膜支架 5 例。术后随访 2 ~ 34 个月,平均 19 个月。术后 6、12 个月电话随访。6 例患者彩色多普勒超声或 CTA 示支架内血管通畅,无内漏、支架移位及动脉瘤复发。肾功能检测均正常。术后 1 年 6 例支架均通畅。

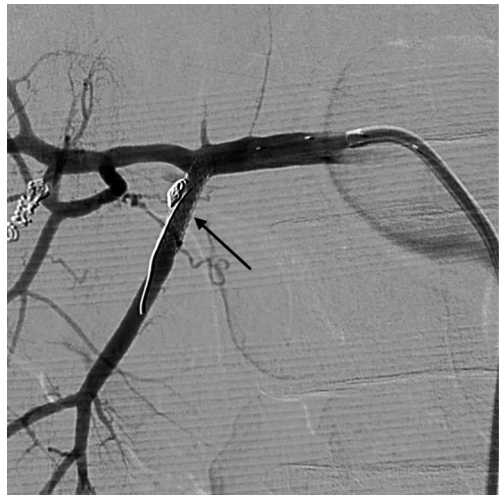

图 1 弹簧圈栓塞联合覆膜支架(黑箭)术后造影示损伤血管无对比剂外溢

3 讨论

肾出血患者多经内科保守治疗后仍尿血致生命体征不稳而就诊,其治疗目的主要是止血。而介入栓塞已成为治疗肾出血的常规治疗方法[3-4]。Eastham 等[5]报道外伤引起的肾出血栓塞成功率达 88%。然而,有报道对于肾动脉主干损伤、孤立肾、肾部分切除术后及合并其他基础疾病 (如糖尿病、高血压、慢性肾脏疾病)患者行常规栓塞后可能致肾功能损伤[6]。本组中 1 例即因 PCNL 术后多支血管受损已行 2 次常规出血动脉栓塞, 术后仍有血尿,最终发现出血点在肾动脉一级分支开口处,而此时复查肾功能肌酐已有升高 (该患者左肾功能也较差)。考虑肾脏灌注情况,尝试给予冠状动脉球扩式覆膜支架植入封堵破口并保留该一级分支,最终成功止血的同时还维持肾脏灌注(图 1)。该例患者术后第 2 天血尿停止,各项生化指标逐渐好转。介入术后 2 周复查肾功能肌酐逐渐下降但仍未恢复正常, 术后 3 个月电话随访患者肾功能检查正常,彩色多普勒超声检查血管内支架通畅。

肾脏假性动脉瘤治疗的首要目标是控制远期并发症及维持血流动力学稳定。根据假性动脉瘤部位,临床上分为肾内型和肾外型,肾内型假性动脉瘤多为医源性损伤包括经皮活检、经皮肾镜取石、微波碎石、外科开放性手术等。肾内型假性动脉瘤常规超选择性动脉栓塞能有效栓塞动脉瘤并能最大程度维持肾脏灌注,在临床应用中日趋成熟。肾移植术后并发肾外型假性动脉瘤罕见,其发生率仅 0.3%[7]。可能与血管壁的损伤、缝合技术不佳、感染及免疫因素等有关,临床表现不典型,多数无明显

症状,本组患者多表现为肾功能异常,且多发生于术后早期(平均为术后 42.5 d),易误认为肾移植术后排斥反应, 因此对其早期鉴别诊断有重要意义。肾外型假性动脉瘤行常规栓塞将导致远端肾实质灌注不足甚至整个移植肾功能丧失。外科切除围手术期死亡率达 3%,严重并发症发生率高达 17%[8-9],且存在较高的死亡率及复发率,包括移植肾切除的风险也较高[10]。Reus 等[11]报道超声引导下经皮瘤内注射凝血酶成功治疗 1 例髂外动脉假性动脉瘤,但这种治疗可能出现动脉瘤破裂、凝血酶过敏、皮肤坏死、动静脉瘘、感染及远端血管栓塞。Garrido 等[10]曾报道血管内弹簧圈栓塞未能达到长久栓塞假性动脉瘤的目的。正因其不足之处,覆膜支架开始应用于内脏动脉假性动脉瘤如肝动脉、胰动脉[7,12],尤其对于缺乏侧支循环的终末型动脉供血器官肾脏,血管内支架能成功封堵瘘口且不影响远端肾实质血流。曾有个案报道覆膜支架应用于移植肾假性动脉瘤的治疗[13-14]。本组 2 例患者为移植肾动脉与髂外动脉端侧吻合,吻合口处假性动脉瘤行髂外动脉支架植入术(图 2),术后患者症状逐渐好转,术后 3 d 血肌酐下降,但移植肾功能丧失。1 例患者术后 1 周出现不明原因感染,再次行移植肾切除术。1 例肾移植患者术后半年 CT 复查示髂外动脉支架内血流通畅。有报道髂动脉动脉瘤支架术后 4 年通畅率达 88%[15]。假性动脉瘤位于髂外动脉吻合口或距吻合口较近时行覆膜支架达到封堵瘤腔同时栓塞移植肾的效果,待患者生命体征平稳后再作后续处理。2 例肾移植患者为髂内动脉吻合口假性动脉瘤 (图 3),覆膜支架可跨越瘘口置于髂内动脉和移植肾动脉内,因此术后既治疗了动脉瘤又保证了移植肾脏的血流灌注,术中造影无内漏且支架位置良好。其中 1 例因吻合口双动脉瘤且解剖结构复杂而行髂内双支架植入术,术后 1 周彩色多普勒超声示支架内血流通畅, 支架吻合口处一宽约 1.5 mm 的残余分流,血流缓慢。2 个月后彩色多普勒超声示血栓形成,分流消失,目前仍在继续随访中。文献报道肾脏假性动脉瘤覆膜支架的应用多为个案报道,随访时间均较短,其中随访最长者为 3 年,支架内无狭窄、感染及动脉瘤复发[13-14,16-20]。结合文献报道及本研究显示覆膜支架植入技术成功率较高,围手术期无严重并发症,近期通畅率高。本组患者 1 年通畅率达 100%。其中 1 例随访 34 个月支架通畅。6 例患者支

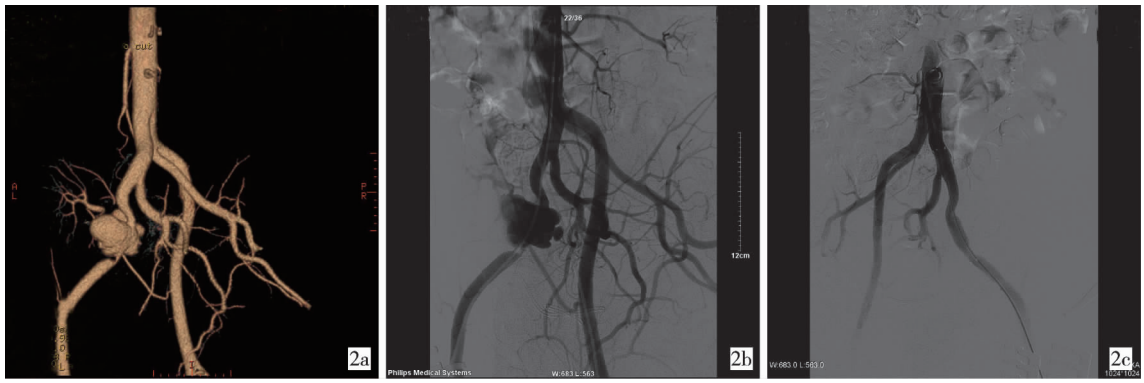

2a 术前 CTA 示左髂外移植肾吻合口假性动脉瘤 **2b** DSA 造影示左髂外吻合口假性动脉瘤 **2c** 术后 DSA 造影示瘤腔消失, 移植肾未显影

图 2 左侧移植肾髂外动脉支架植入术前、术后所见

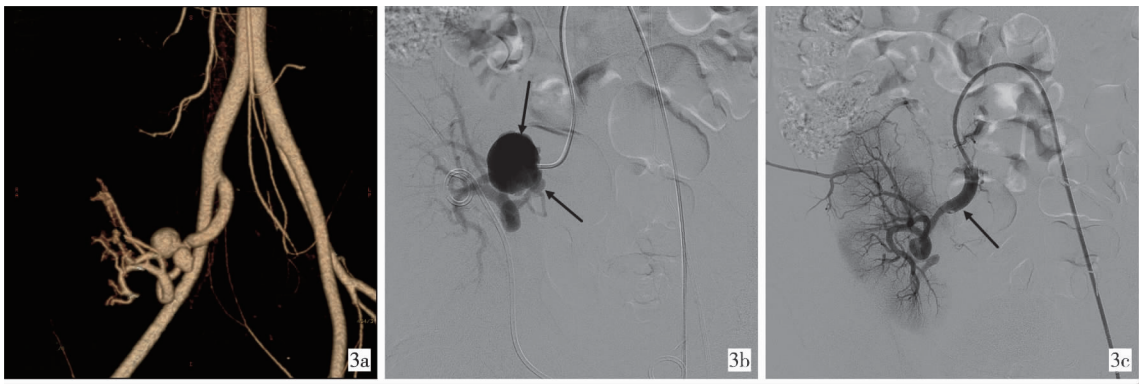

3a CTA 示右髂内 2 个假性动脉瘤 **3b** DSA 造影示右髂内 2 个动脉瘤 (黑箭)与术前 CTA 相符 **3c** 术后 DSA 造影示支架位置良好 (黑箭),假性动脉瘤消失且移植肾保留

图 3 右髂内动脉瘤术前、术后所见

架植入术后肾功能均较前好转或恢复正常,尤其对于髂内动脉移植肾患者可能挽救其肾功能。

另外,血管直径及顺应性是应用覆膜支架的限制,文献报道对于直径 < 6 mm 的血管有血栓形成的危险不推荐使用[21]。这就限制了直径小且迂曲的血管支架的应用。但目前还缺乏长期随访数据证实。

总之,对于肾内型动脉主干或肾外型假性动脉瘤及其本身疾病不宜常规介入栓塞的患者,血管内覆膜支架安全有效,损伤小,技术成功率高,近期效果明显,是一种安全的手术替代方法。但支架远期的通畅率及稳定性还需长期随访。

[参 考 文 献]

[1] Dib M, Sedat J, Raffaelli C, et al. Endovascular treatment of a wide-neck renal artery bifurcation aneurysm [J]. J Vasc Interv Radiol, 2003, 14: 1461 - 1464.

[2] Henke PK, Cardneau JD, Welling TH 3rd, et al. Renal artery aneurysms: a 35-year clinical experience with 252 aneurysms in 168 patients[J]. Ann Surg, 2001, 234: 454 - 462.

[3] Hislop SJ, Patel SA, Abt PL, et al. Therapy of renal artery aneurysms in New York State: outcomes of patients undergoing open and endovascular repair [J]. Ann Vasc Surg, 2009, 23: 194 - 200.

[4] Cimsit NC, Baltacioglu F, Cengic I, et al. Transarterial glue embolization in iatrogenic renovascular injuries [J]. Int Urol Nephrol, 2008, 40: 875 - 879.

[5] Eastham JA, Wilson TG, Larsen DW, et al. Angiographic embolization of renal stab wounds[J]. J Urol, 1992, 148: 268 - 270.

[6] Rami P, Williams D, Forauer A, et al. Stent-graft treatment of patients with acute bleeding from hepatic artery branches [J]. Cardiovasc Intervent Radiol, 2005, 28: 153 - 158.

[7] Dimitroulis D, Bokos J, Zavos G, et al. Vascular complications in renal transplantation: a single-center experience in 1 367 renal transplantations and review of the literature[J]. Transplant Proc, 2009, 41: 1609 - 1614.

[8] English WP, Pearce JD, Carven TE, et al. Surgical management of renal artery aneurysms[J]. J Vasc Surg, 2004, 40: 53 - 60.

[9] Pfeiffer T, Reiher L, Grabitz K, et al. Reconstruction for renal artery aneurysm: operative techniques and long-term results[J]. J Vasc Surg, 2003, 37: 293 - 300.

[10] Garrido J, Lerma JL, Heras M, et al. Pseudoaneurysm of the iliac artery secondary to Aspergillus infection in two recipients of kidney transplants from the same donor [J]. Am J Kidney Dis, 2003, 41: 488 - 492.

[11] Reus M, Morales D, Vázquez V, et al. Ultrasound-guided percutaneous thrombin injection for treatment of extrarenal pseudoaneurysm after renal transplantation [J]. Transplantation, 2002, 74: 882 - 884.

[12] Pasklinsky G, Gasparis AP, Labropoulos N, et al. Endovascular covered stenting for visceral artery pseudoaneurysm rupture: report of 2 cases and a summary of the disease process and treatment options[J]. Vasc Endovascular Surg, 2009, 42: 601 - 606.

[13] Philippou P, Moraitis K, El-Husseiny T, et al. Endovascular covered stenting for the management of post-percutaneous nephrolithotomy renal pseudoaneurysm: a case report [J]. J Med Case Reports, 2010, 4: 316.

[14] Horwitz MD, Hanbury DC, King CM. Renal artery pseudoaneurysm following partial nephrectomy treated with stent-graft[J]. Br J Radiol, 2005, 78: 161 - 163.

[15] Scheinert D, Schröder M, Steinkamp H, et al. Treatment of iliac artery aneurysms by percutaneous implantation of stent grafts[J]. Circulation, 2000, 102: Ⅲ253 - Ⅲ258.

[16] Bracale UM, Santangelo M, Carbone F, et al. Anastomotic pseudoaneurysm complicating renal transplantation: treatment options[J]. Eur J Vasc Endovasc Surg, 2010, 39: 565 - 568.

[17] Kubal C, Cacciola R, Riley P, et al. Internal iliac artery pseudoaneurysm following renal transplant biopsy successfully treated with endovascular stenting and thrombosis: a case report [J]. Transplant Proc, 2007, 39: 1676 - 1678.

[18] Moosavi CA, Gujrathi SK, Friedman A, et al. Endovascular repair of symptomatic renal transplant site pseudoaneurysm[J]. Vasc Endovascular Surg, 2008, 42: 607 - 609.

[19] 聂海波, 何恢绪, 刘 东, 等. 移植肾动脉狭窄及移植肾动脉瘤 9 例介入治疗总结[J]. 第一军医大学学报, 2003, 23: 277 - 278.

[20] Zavos G, Pappas P, Kakisis JD, et al. Endovascular repair as first-choice treatment of iliac pseudoaneurysms following renal transplantation[J]. Transplant Proc, 2005, 37: 4300 - 4302.

[21] Nosher JL, Chung J, Brevetti LS, et al. Visceral and renal artery aneurysms: a pictorial essay on endovascular therapy [J]. Radiographics, 2006, 26: 1687 - 1704.

(收稿日期:2012-10-22)
(本文编辑:侯虹鲁)